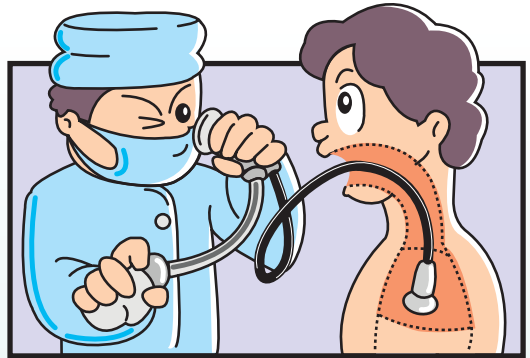


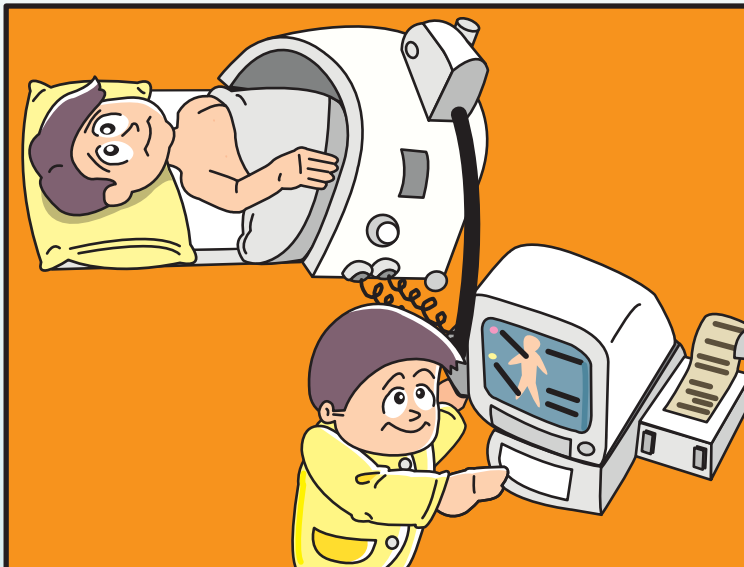
Other lung diseases that may mimic tuberculosis



Other diseases such as pneumonia and lung cancer can cause similar symptoms and chest X-ray findings as active TB disease. When active TB disease cannot be bacteriologically confirmed by sputum examination, further investigation (such as fiberoptic bronchoscopy, computed tomography scan of the Chest) may be required.



Bronchoscopy



CT Scan